

Navigation-related structural change in the hippocampi of taxi drivers

Eleanor A. Maguire^{*†}, David G. Gadian[†], Ingrid S. Johnsrude[†], Catriona D. Good[†], John Ashburner[†], Richard S. J. Frackowiak[†], and Christopher D. Frith[†]

[†]Wellcome Department of Cognitive Neurology, Institute of Neurology, University College London, Queen Square, London WC1N 3BG, United Kingdom; and ^{*}Radiology and Physics Unit, Institute of Child Health, University College London, London WC1N 1EH, United Kingdom

Communicated by Brenda Milner, McGill University, Montreal, Canada, January 28, 2000 (received for review November 10, 1999)

Structural MRIs of the brains of humans with extensive navigation experience, licensed London taxi drivers, were analyzed and compared with those of control subjects who did not drive taxis. The posterior hippocampi of taxi drivers were significantly larger relative to those of control subjects. A more anterior hippocampal region was larger in control subjects than in taxi drivers. Hippocampal volume correlated with the amount of time spent as a taxi driver (positively in the posterior and negatively in the anterior hippocampus). These data are in accordance with the idea that the posterior hippocampus stores a spatial representation of the environment and can expand regionally to accommodate elaboration of this representation in people with a high dependence on navigational skills. It seems that there is a capacity for local plastic change in the structure of the healthy adult human brain in response to environmental demands.

One important role of the hippocampus is to facilitate spatial memory in the form of navigation (1). Increased hippocampal volume relative to brain and body size has been reported in small mammals and birds who engage in behavior requiring spatial memory, such as food storing (2). In some species, hippocampal volumes enlarge specifically during seasons when demand for spatial ability is greatest (2, 3). In the healthy human, structural brain differences between distinct groups of subjects (for example, males and females, ref. 4, or musicians and nonmusicians, ref. 5) have been documented. From existing studies, it is impossible to know whether differences in brain anatomy are predetermined or whether the brain is susceptible to plastic change in response to environmental stimulation. Furthermore, although lesion work (6, 7) and functional neuroimaging work (8) confirm the involvement of the human hippocampus in spatial memory and navigation, there is still debate about its precise role. Given the propensity of lower mammalian/avian hippocampi to undergo structural change in response to behavior requiring spatial memory (2, 3), the present study addressed whether morphological changes could be detected in the healthy human brain associated with extensive experience of spatial navigation. Our prediction was that the hippocampus would be the most likely brain region to show changes.

Taxi drivers in London must undergo extensive training, learning how to navigate between thousands of places in the city. This training is colloquially known as “being on The Knowledge” and takes about 2 years to acquire on average. To be licensed to operate, it is necessary to pass a very stringent set of police examinations. London taxi drivers are therefore ideally suited for the study of spatial navigation. The use of a group of taxi drivers with a wide range of navigating experience permitted an examination of the direct effect of spatial experience on brain structure. In the first instance, we used voxel-based morphometry (VBM) to examine whether morphological changes associated with navigation experience were detectable anywhere in the healthy human brain. VBM is an objective and automatic procedure that identifies regional differences in relative gray matter density in structural MRI brain scans. It allows every point in the brain to be considered in an unbiased way, with no

a priori regions of interest. The data were also analyzed by using a second and completely independent pixel-counting technique within the hippocampus proper. Comparisons were made between the brain scans of taxi drivers, who had all acquired a significant amount of large-scale spatial information (as evidenced by passing the licensing examinations), and those of a comparable group of control subjects who lacked such extensive navigation exposure.

Methods

Subjects. Right-handed male licensed London taxi drivers ($n = 16$; mean age 44 years; range 32–62 years) participated. All had been licensed London taxi drivers for more than 1.5 years (mean time as taxi driver = 14.3 years; range = 1.5–42 years). The average time spent training to be a taxi driver before passing the licensing tests fully (i.e., time on The Knowledge) was 2 years (range 10 months to 3.5 years; some trained continuously, some part time). All of the taxi drivers had healthy general medical, neurological, and psychiatric profiles. The scans of control subjects were selected from the structural MRI scan database at the same unit where the taxi drivers were scanned. Those subjects below 32 and above 62 years of age were excluded as were females, left-handed males, and those with any health problems. After the application of these exclusion criteria, the scans of 50 healthy right-handed males who did not drive taxis were included in the analyses for comparison with the taxi drivers. Both the mean age and the age range did not differ between the taxi driver and control groups. We were also careful to ensure an even spread of subjects in each decade (for example, 41–50 years or 51–60 years) up to the upper limit of the oldest taxi driver, such that subjects were not clustered at one end of the age scale.

Image Acquisition. Structural MRI scans were obtained with a 2.0 Tesla Vision system (Siemens GmbH, Erlangen, Germany) by using a T1-weighted three-dimensional gradient echo sequence (TR 9.7 ms; TE 4 ms; flip angle 12°; field of view 256 mm; 108 partitions; partition thickness 1.5 mm; voxel size $1 \times 1 \times 1.5$ mm).

Image Analysis Method 1: VBM. Data were analyzed by using VBM implemented with Statistical Parametric Mapping (SPM99, Wellcome Department of Cognitive Neurology) executed in MATLAB (Mathworks, Sherborn, MA). Detailed descriptions of the technique are given elsewhere (9, 10). Briefly, the subjects' data were spatially normalized into stereotactic space (11) by registering each of the images to the same template image by minimizing the residual sums of squared differences between them. The template

Abbreviations: VBM, voxel-based morphometry; ICV, intracranial volume.

*To whom reprint requests should be addressed. E-mail: e.maguire@fil.ion.ucl.ac.uk.

The publication costs of this article were defrayed in part by page charge payment. This article must therefore be hereby marked “advertisement” in accordance with 18 U.S.C. §1734 solely to indicate this fact.

Article published online before print: *Proc. Natl. Acad. Sci. USA*, 10.1073/pnas.070039597. Article and publication date are at www.pnas.org/cgi/doi/10.1073/pnas.070039597

was generated from the structural scans of 50 healthy males acquired in the same scanner used to collect the data for the current analysis (the scans of 13 of the control subjects used in the VBM analysis were included in the creation of this template). The spatially normalized images were written in voxels of $1.5 \times 1.5 \times 1.5$ mm and segmented into gray matter, white matter, and cerebrospinal fluid by using a modified mixture cluster analysis technique. To reduce confounds caused by individual differences in gyral anatomy, the gray matter images were smoothed by using an isotropic Gaussian kernel of 4-mm full width at half maximum. The statistical model included a measure of total amount of gray matter in each brain as a confound (essentially the original values before normalization). Statistical tests involved locating regionally specific differences in gray matter between subject groups and were based on *t* tests and the general linear model. Significance levels were set at $P < 0.05$ (small volume correction for multiple comparisons, with 62 resolution elements comprising the volume of interest). To be consistent across the two analysis techniques, we defined the hippocampal regions the same way in both cases as described below.

Image Analysis Method 2: Pixel Counting. The three-dimensional images from the 16 taxi drivers and a precisely age-matched sample of 16 normal controls taken from the 50 used in the VBM analysis were submitted for region-of-interest-based volumetric measurement of both hippocampi by using a well established pixel-counting technique (12, 13). The images were analyzed by one person experienced in the technique and blinded to subjects' identity as taxi drivers or controls and the VBM findings. Briefly, the images were reformatted into 1.5-mm-thick contiguous sections in a tilted coronal plane that was perpendicular to the long axis of the hippocampus. Hippocampal cross-sectional areas were measured for each slice along the whole length of the hippocampus. There were at least 26 contiguous slices (each 1.5-mm-thick) for each hippocampus of each subject, giving a total length of approximately 4 cm. Total hippocampal volume was calculated by summing the cross-sectional areas and multiplying by the distance between adjacent slices (i.e., 1.5 mm). These volumes were then corrected for intracranial volume (ICV), which was measured from the sagittal slices of the original three-dimensional data sets. Measurements for the most posterior slices violated assumptions of homogeneity of variance and were therefore not considered in the analyses, leaving the measurements for 24 slices. These were grouped into three regions (14): posterior hippocampus (6 slices), body (12 slices), and anterior (6 slices). Values for the component slices for a particular region were averaged, and the data were analyzed by ANOVA and correlations (significance level set at $P < 0.05$). We report the analyses on data uncorrected for ICV (when data were corrected for ICV, the results did not differ).

Results

VBM. Significantly increased gray matter volume was found in the brains of taxi drivers compared with those of controls in only two brain regions, namely the right and the left hippocampi (Fig. 1 *a* and *b*). No differences were observed elsewhere in the brain. The increase in hippocampal gray matter volume was focal and limited to the posterior hippocampus bilaterally. The voxel of peak difference in gray matter density in the right hippocampus was at (x, y, z) 31, -22 , -13 ($Z = 4.34$) and, in the left hippocampus, was at -31 , -28 , -10 ($Z = 4.19$). The area of difference extended in the *y* axis in the right hippocampus from -17 mm to -33 mm and in the left hippocampus from -18 mm to -34 mm. Controls showed a relatively greater gray matter volume bilaterally in anterior hippocampi relative to those of taxi drivers (Fig. 1*c*). The voxel of peak difference in gray matter density in the right hippocampus was at 32 , -7 , -28 ($Z = 2.65$) and in the left hippocampus was at -34 , -7 , -26 ($Z = 2.65$). The anterior changes did not survive correction for multiple com-

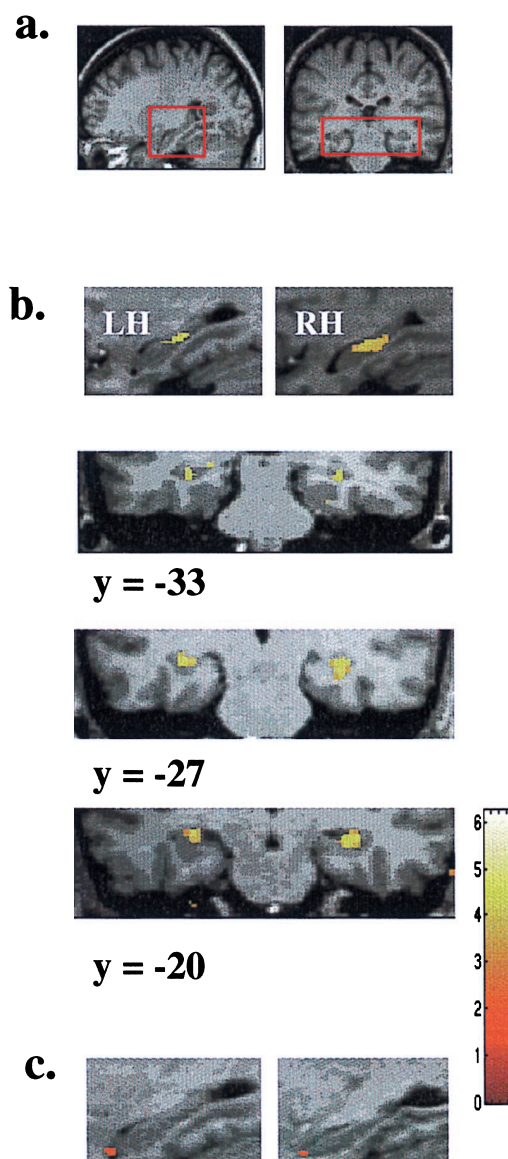


Fig. 1. VBM findings. (*a Left*) Sagittal section of an MRI scan with the hippocampus indicated by the red box. (*a Right*) Coronal section through the MRI scan, again with the hippocampi indicated. (*b*) The group results are shown superimposed onto the scan of an individual subject selected at random. The bar to the right indicates the Z score level. Increased gray matter volume in the posterior of the left and right hippocampi (LH and RH, respectively) of taxi drivers relative to those of controls, shown in the top of the figure in sagittal section. Underneath, the areas of gray matter difference are shown in coronal sections at three different coordinates in the *y* axis to illustrate the extent of the difference down the long axis of the hippocampus. (*c*) Increased gray matter volume in the anterior of the left and right hippocampi of controls relative to those of taxi drivers, shown in sagittal section. Note that, although the Talairach and Tournoux (11) coordinate system was used to describe the locations of VBM differences in stereotactic space, the images were normalized with respect to a template based on a large number of brains scanned in the same scanner used to collect the current data (see *Methods*). Thus, the coordinates given refer to our brain template and only approximately to the Talairach and Tournoux template.

parisons but were confirmed in the second analysis technique as described below.

Pixel Counting. Hippocampal volumes (both corrected and uncorrected for ICV) and ICV did not differ significantly between

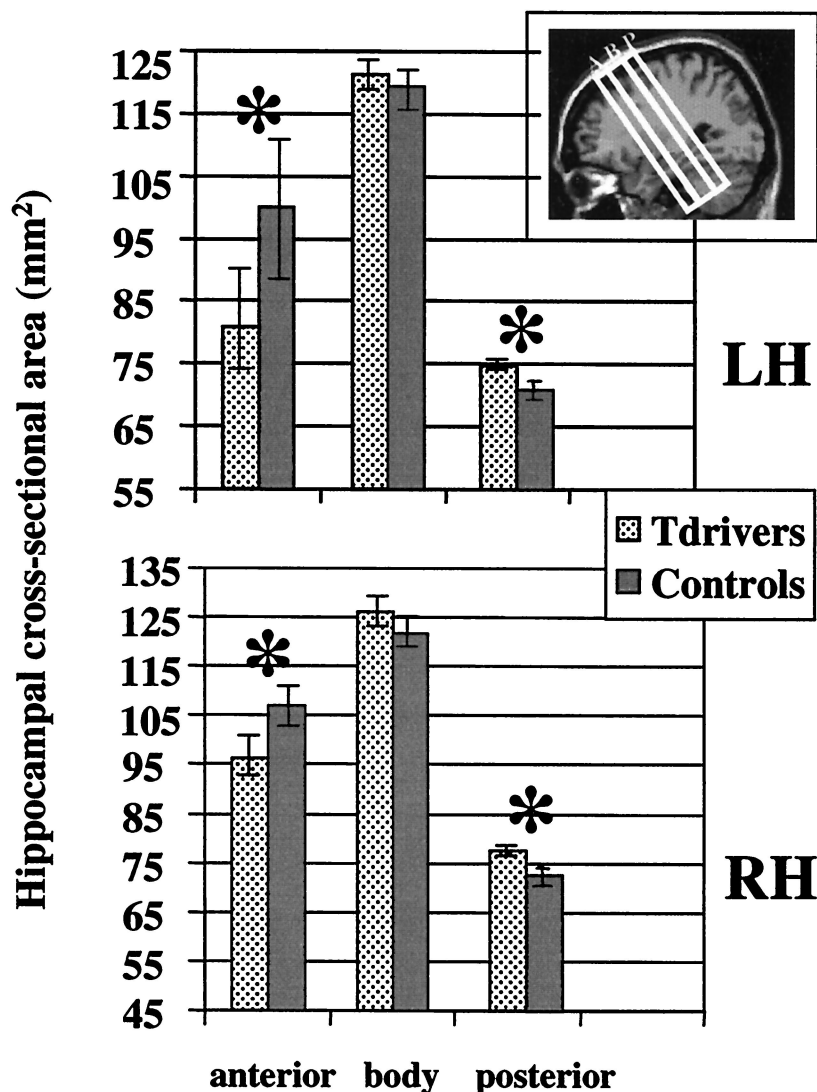


Fig. 2. Volumetric analysis findings. The orientation of the slices measured in the volumetric analysis with respect to the hippocampus is shown (*Top Right Inset*). A, anterior; B, body; P, posterior. (*Upper*) The mean of the cross-sectional area measurements (uncorrected for ICV) for the three regions of the left hippocampus (LH). (*Lower*) The means for the right hippocampus (RH). Taxi drivers had a significantly greater volume relative to controls in the posterior hippocampus, and controls showed greater hippocampal volume in the anterior. There was no difference between the two groups in the hippocampus body. *, $P < 0.05$.

the two subject groups [right hippocampus: taxi drivers, uncorrected = $4,300 \text{ mm}^3 (\pm 432)$, corrected = $4,159 \text{ mm}^3 (\pm 420)$; controls, uncorrected = $4,255 \text{ mm}^3 (\pm 424)$, corrected = $4,080 \text{ mm}^3 (\pm 325)$; left hippocampus: taxi drivers, uncorrected = $4,155 \text{ mm}^3 (\pm 410)$, corrected = $3,977 \text{ mm}^3 (\pm 350)$; controls, uncorrected = $4,092 \text{ mm}^3 (\pm 324)$, corrected = $3,918 \text{ mm}^3 (\pm 224)$; ICV of taxi drivers = $1,521 \text{ mm}^3 (\pm 145)$; controls = $1,540 \text{ mm}^3 (\pm 107)$].

Although the analysis revealed no difference in the overall volume of the hippocampi between taxi drivers and controls, it did reveal regionally specific differences in volume (Fig. 2). ANOVA (group by side) on anterior hippocampal volumes revealed a main effect of group, with control volumes significantly greater than those in taxi drivers [df (1, 30); $F = 5$; $P < 0.05$], a main effect of side, with the anterior right hippocampus being larger than the left [df (1, 30); $F = 4.5$; $P < 0.05$], and no interaction. Analysis of the volumes for the body of the hippocampus showed no interaction and no effect of group but a main effect of side, again right greater than left [df (1, 30); $F = 5.4$; $P < 0.05$]. Finally, analysis of volumes of the posterior

hippocampus revealed a main effect of group, with taxi drivers having a greater posterior hippocampal volume than controls [df (1, 30); $F = 4.1$; $P < 0.05$]. Neither the interaction nor the main effect of side was significant.

Changes with Navigation Experience. We examined the correlation between volume and amount of time spent as a taxi driver (including both training on The Knowledge and practicing as a qualified taxi driver). We found that length of time spent as a taxi driver correlated positively with volume in only one brain region, the right posterior hippocampus (Fig. 3*a*). Correction for age was made by including it as a confounding covariate. The voxel of peak correlation in the right hippocampus was at 22, -33, 3 ($Z = 5.65$). The extent of the area in the right hippocampus ranged in the y axis from -29 mm to -36 mm. The spatial extent of this area overlapped with the area showing greater volume in the categorical comparison of taxi drivers with controls. The VBM changes as a function of time (in months) spent as a taxi driver (corrected for age effects) and global gray matter are plotted in Fig. 3*b*, where the data were considered within a linear model

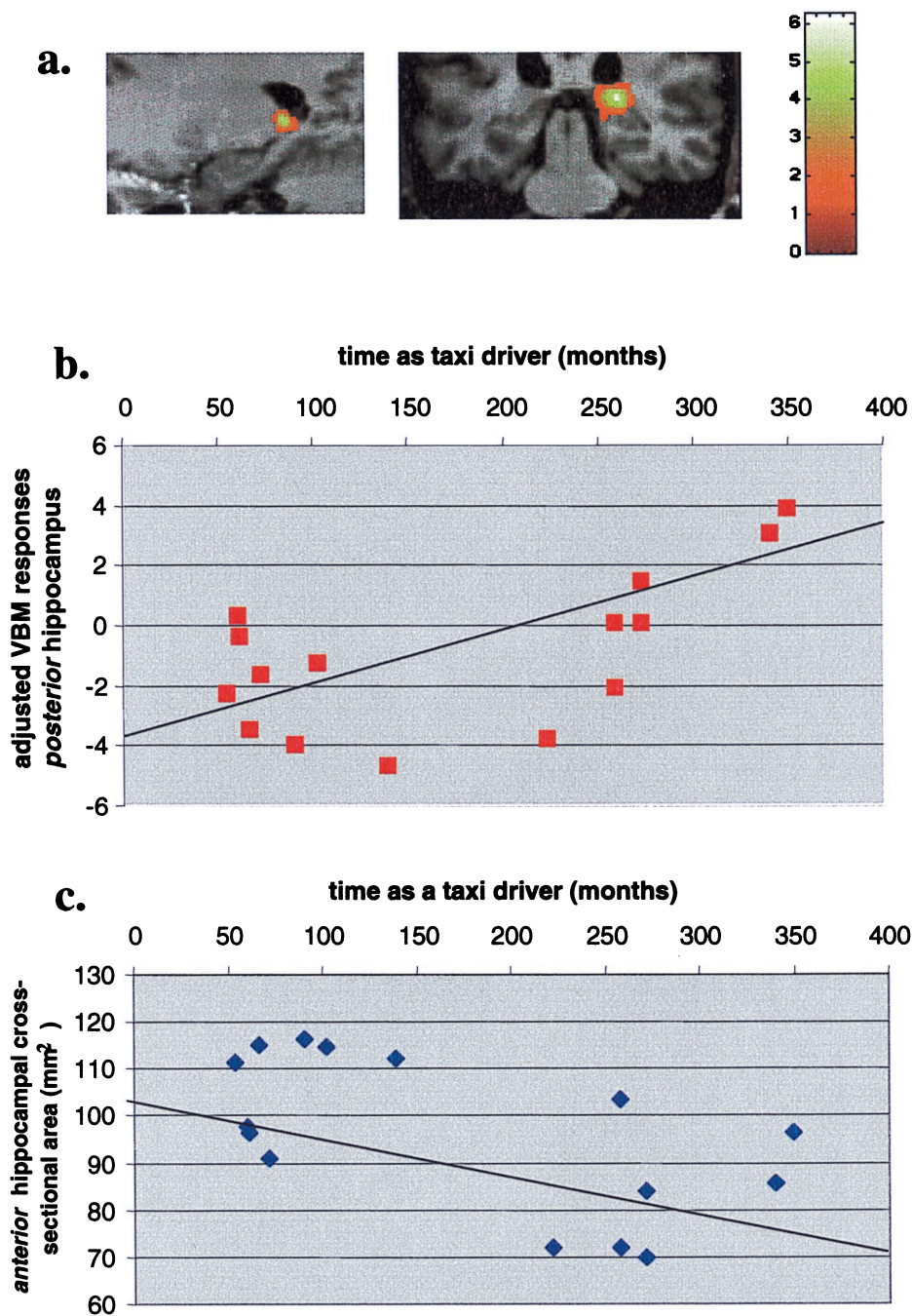


Fig. 3. Correlation of volume change with time as a taxi driver. *(a Left)* Sagittal section. *(a Right)* Coronal section. The VBM group results are shown superimposed onto the scan of an individual subject selected at random. The bar to the right indicates the Z score level. The volume of gray matter in the right hippocampus was found to correlate significantly with the amount of time spent learning to be and practicing as a licensed London taxi driver, positively in the right posterior hippocampus *(b)* and negatively in the anterior hippocampus *(c)*.

($r = 0.6$; $P < 0.05$). The correlation between time spent as a taxi driver (corrected for age) and the pixel-counting data indicated a similar relationship for the posterior hippocampus ($r = 0.5$; $P < 0.06$). The pixel-counting data also showed a negative correlation between the time spent as a taxi driver and the volume of anterior hippocampal tissue ($r = -0.6$; $P < 0.05$) as plotted in Fig. 3c. When time as a taxi driver was corrected for age by expressing it as a percentage of age, the result was identical ($r = -0.6$; $P < 0.05$). The data of one taxi driver were not included in the correlation analyses. He had been a taxi driver for 42 years, and the next nearest length of time was 28 years; thus, he was

treated as an outlier and removed. The data of this subject were completely in line with the relationships as plotted; for example, his VBM response measure was 13.7.

Discussion

The data presented in this report provide evidence of regionally specific structural differences between the hippocampi of licensed London taxi drivers compared with those of control subjects. Taxi drivers had a significantly greater volume in the posterior hippocampus, whereas control subjects showed greater volume in the anterior hippocampus. The converging results

from these two independent analysis techniques indicate that the professional dependence on navigational skills in licensed London taxi drivers is associated with a relative redistribution of gray matter in the hippocampus. We further considered whether the volume differences between the groups could be incidental and unassociated with the navigational requirements of the taxi drivers. For example, could this particular arrangement of hippocampal gray matter predispose individuals to professional dependence on navigational skills? Although this explanation would be fascinating in itself, we tested this notion directly by examining the correlation between volume and amount of time spent as a taxi driver. Right hippocampal volume correlated with the amount of time spent as a taxi driver (positively in the posterior and negatively in the anterior hippocampus). We believe that these data suggest that the changes in hippocampal gray matter—at least on the right—are acquired. As such, this finding indicates the possibility of local plasticity in the structure of the healthy adult human brain as a function of increasing exposure to an environmental stimulus.

Previous rodent and monkey studies have found the dorsal (posterior) hippocampus to be preferentially involved in spatial navigation (15–18). Such an involvement may also be true for the rostral part of the hippocampus in birds (19). There are also many more cells with spatial correlates—place cells (20)—in the dorsal than in the ventral rat hippocampus (21). Functional neuroimaging studies of navigation in humans show that the retrieval or use of previously learned navigational information is associated with activation of the posterior hippocampus (22–24). Patients with lesions of the hippocampus that spare the posterior aspect have been reported to be unimpaired at recalling routes learned before lesion onset (6). Exactly how much posterior hippocampus needs to be spared to support the recall of “old” cognitive maps is not clear. For instance, it has been reported recently that a patient with extensive damage to the medial temporal region bilaterally, including the hippocampus, could recall the town where he grew up many years before (25). The authors of that report inferred from this fact that the medial temporal region is not the repository of spatial maps. However, they also allude to some sparing of the hippocampal tissue near the lateral ventricles bilaterally. It is therefore not clear whether this tissue was contributing to the recall of the patient’s spatial map. Unfortunately, the patient was not tested by using functional neuroimaging during the recall of these old memories, which could have confirmed whether the remaining hippocampal tissue was still functional. We would predict that it was.

Our finding that the posterior hippocampus increases in volume when there is occupational dependence on spatial navigation is evidence for functional differentiation within the hippocampus. In humans, as in other animals, the posterior hippocampus seems to be preferentially involved when previously learned spatial information is used, whereas the anterior hippocampal region may be more involved (in combination with the posterior hippocampus) during the encoding of new environmental layouts.

A basic spatial representation of London is established in the taxi drivers by the time The Knowledge is complete. This representation of the city is much more extensive in taxi drivers

than in the control subjects. Among the taxi drivers, there is, over time and with experience, a further fine-tuning of the spatial representation of London, permitting increasing understanding of how routes and places relate to each other. Our results suggest that the “mental map” of the city is stored in the posterior hippocampus and is accommodated by an increase in tissue volume. These results challenge the traditional view that the hippocampus has a transient role in memory (26) at least in relation to spatial navigation and the posterior hippocampus. The need to navigate is a basic cross-species behavior. The hippocampus is a phylogenetically old part of the brain, with an intrinsic circuitry that may have evolved to deal with navigation. Undoubtedly, in humans, the functions of the hippocampus have adapted to accommodate other types of memory, such as episodic memory (27–29), but the hippocampus retains an ability to store large-scale spatial information (1).

Our findings from two independent measurement techniques are consistent with patient (6) and functional neuroimaging (22) reports of bilateral hippocampal involvement in successful navigation. Unlike right hippocampal volume, however, left hippocampal volume did not correlate with years of taxi-driving experience, suggesting that the left hippocampus participates in spatial navigation and memory in a different way from the right hippocampus. We may speculate that the left hippocampus complements its partner by storing memories of people and events that occur in the rich context of taxi driving in the real world, where an over-arching framework—such as integrating information into an existing map—is not required (30).

Although the hippocampus does not support navigation in isolation from other brain regions, it seems to be crucial to the storage and use of mental maps of our environments. The prolonged accumulation of other types of nonnavigational information may also produce similar hippocampal changes. Our present findings, however, corroborated as they are by the results of patient and neuroimaging studies, suggest that space and the posterior right human hippocampus are intimately linked.

Given the macroscopic level of our analyses, the data do not speak directly to the microscopic mechanisms, such as neurogenesis (31–33), that might underlie the structural change we report herein. The differential changes in posterior and anterior hippocampus may represent two separate processes. The most parsimonious explanation, however, is that our findings reflect an overall internal reorganization of hippocampal circuitry (34) in response to a need to store an increasingly detailed spatial representation, where changes in one hippocampal region are very likely to affect others. On a broader level, the demonstration that normal activities can induce changes in the relative volume of gray matter in the brain has obvious implications for rehabilitation of those who have suffered brain injury or disease. It remains to be seen whether similar environment-related plasticity is possible in other regions of the human brain outside of the hippocampus.

E.A.M., I.S.J., C.D.G., J.A., R.S.J.F., and C.D.F. are supported by the Wellcome Trust. D.G.G. thanks the Wellcome Trust for its support at the Institute of Child Health. We are grateful for the assistance of Helen Gallagher, Amanda Brennan, and Jon Galliers. We also thank Andrew Holmes, Cheryl Johnson, and David McGonigle.

- O’Keefe, J. & Nadel, L. (1978) *The Hippocampus as a Cognitive Map* (Clarendon, Oxford).
- Lee, D. W., Miyasato, L. E. & Clayton, N. S. (1998) *NeuroReport* **9**, R15–R27.
- Smulders, T. V., Sasson, A. D. & DeVoogd, T. J. (1995) *J. Neurobiol.* **27**, 15–25.
- Gur, R. C., Turetsky, B. I., Matsui, M., Yan, M., Bilker, W., Hughett, P. & Gur, R. E. (1999) *J. Neurosci.* **19**, 4065–4072.
- Schlaug, G., Jancke, L., Huang, Y. & Steinmetz, H. (1995) *Science* **267**, 699–701.
- Maguire, E. A., Burke, T., Phillips, J. & Staunton, H. (1996) *Neuropsychologia* **34**, 993–1001.
- Smith, M. L. & Milner, B. (1981) *Neuropsychologia* **19**, 781–793.
- Maguire, E. A., Burgess, N. & O’Keefe, J. (1999) *Curr. Opin. Neurobiol.* **9**, 171–177.
- Wright, I. C., McGuire, P. K., Poline, J.-B., Travers, J. M., Murray, R. M., Frith, C. D., Frackowiak, R. S. J. & Friston, K. J. (1995) *Neuroimage* **2**, 244–252.
- May, A., Ashburner, J., Büchel, C., McGonigle, D. J., Friston, K. J., Frackowiak, R. S. J. & Goadsby, P. J. (1999) *Nat. Med.* **5**, 836–838.
- Talairach, J. & Tournoux, P. (1988) *Coplanar Stereotaxic Atlas of the Human Brain* (Thieme, Stuttgart).
- Van Paesschen, W., Connolly, A., King, M. D., Jackson, G. D. & Duncan, J. S. (1997) *Ann. Neurol.* **41**, 41–51.
- Vargha-Khadem, F., Gadian, D. G., Watkins, K. E., Connelly, A., Van Paesschen, W. & Mishkin, M. (1997) *Science* **277**, 376–380.

14. Duvernoy, H. M. (1998) *The Human Hippocampus* (Springer, Berlin).
15. Moser, M. B., Moser, E. I., Forrest, E., Andersen, P. & Morris, R. G. (1995) *Proc. Natl. Acad. Sci. USA* **92**, 9697–9701.
16. Moser, E. I., Moser, M. B. & Andersen, P. (1993) *J. Neurosci.* **13**, 3916–3925.
17. Hock, B. J. & Bunsey, M. D. (1998) *J. Neurosci.* **18**, 7027–7032.
18. Colombo, M., Fernandez, T., Nakamura, K. & Gross, C. G. (1998) *J. Neurophysiol.* **80**, 1002–1005.
19. Clayton, N. S. (1995) *Hippocampus* **5**, 499–510.
20. O'Keefe, J. & Dostrovsky, J. (1971) *Brain Res.* **34**, 171–175.
21. Jung, M. W., Wiener, S. I. & McNaughton, B. L. (1994) *J. Neurosci.* **14**, 7347–7356.
22. Maguire, E. A., Burgess, N., Donnett, J. G., Frackowiak, R. S. J., Frith, C. D. & O'Keefe, J. (1998) *Science* **280**, 921–924.
23. Maguire, E. A., Frackowiak, R. S. J. & Frith, C. D. (1997) *J. Neurosci.* **17**, 7103–7110.
24. Ghaem, O., Mellet, E., Crivello, F., Tzourio, N., Mazoyer, B., Berthoz, A. & Denis, M. (1997) *NeuroReport* **8**, 739–744.
25. Teng, E. & Squire, L. R. (1999) *Nature (London)* **400**, 675–677.
26. Squire, L. R. & Knowlton, B. (1995) in *The Cognitive Neurosciences*, ed. Gazzaniga, M. S. (MIT Press, Cambridge, MA), pp. 825–837.
27. Tulving, E. & Markovitsch, H. J. (1998) *Hippocampus* **8**, 198–204.
28. Squire, L. R. & Zola, S. M. (1998) *Hippocampus* **8**, 205–211.
29. Mishkin, M., Vargha-Khadem, F. & Gadian, D. G. (1998) *Hippocampus* **8**, 212–216.
30. Maguire, E. A. & Mummery, C. J. (1999) *Hippocampus* **9**, 54–61.
31. Gould, E., Tanapat, P., Hastings, N. B. & Shors, T. (1999) *Trends Cognit. Sci.* **3**, 186–192.
32. Kempermann, G., Kuhn, H. G. & Gage, F. H. (1998) *J. Neurosci.* **18**, 3206–3212.
33. Gould, E., Reeves, A. J., Graziano, M. S. A. & Gross, C. G. (1999) *Science* **286**, 548–552.
34. Rapp, P. R., Stack, E. C. & Gallagher, M. (1999) *J. Comp. Neurol.* **403**, 459–470.